



Artless solution to resolve the problem of retention in resorbed alveolar ridge cases

Peer review status:

No

Corresponding Author:

Dr. Khurshid Mattoo,
Assistant Professor, Prosthodontics, College of Dental sciences, Hayal Mathar, 13004 - Saudi Arabia

Submitting Author:

Dr. Khurshid Mattoo,
Assistant Professor, Prosthodontics, College of Dental sciences, Hayal Mathar, 13004 - Saudi Arabia

Other Authors:

Dr. Nupur Rathi,
Lecturer, Prosthodontics, Teerthankar dental college, Moradabad\nUttar Pradesh - India

Previous Article Reference: http://www.webmedcentral.com/article_view/4709

Article ID: WMC005629

Article Type: Case Report

Submitted on: 21-Aug-2020, 08:47:44 PM GMT **Published on:** 02-Sep-2020, 11:53:07 PM GMT

Article URL: http://www.webmedcentral.com/article_view/5629

Subject Categories: DENTISTRY

Keywords: obturator, complete denture, flasking, investing, denture processing, stability

How to cite the article: Rathi N, Mattoo K. Artless solution to resolve the problem of retention in resorbed alveolar ridge cases. WebmedCentral DENTISTRY 2020;11(9):WMC005629

Copyright: This is an open-access article distributed under the terms of the [Creative Commons Attribution License \(CC-BY\)](#), which permits unrestricted use, distribution, and reproduction in any medium, provided the original author and source are credited.

Source(s) of Funding:

None

Competing Interests:

None

Artless solution to resolve the problem of retention in resorbed alveolar ridge cases

Author(s): Rathi N, Mattoo K

Abstract

Rarely maxillary completely edentulous ridges resorb to the extent where they pose a challenge to a prosthodontist. However, whenever they resorb, they definitely alter patient compliance towards dental treatment. For any completely edentulous patient, retention is as important as the prosthesis itself. On the contrary, for a prosthodontist, retention means a chance for his patient to adapt. Without retention, every prosthodontist knows that the patient will not wear the prosthesis. More so, retention is a big factor for maxillary completely edentulous arch as the gravity works against it. This article describes a simple common sense resolution to any situation that demands the prosthesis or even an appliance to be light weight. Reduction in weight of the prosthesis enhanced retention in this case.

Introduction

Complete edentulism is a clinical condition that needs an extremely conservative approach. Transition to edentulism may start at any age, but it ends usually after 60 to 65 years of age excluding exceptions. The state of edentulism when complete may last for 20 to 25 years if it is accepted that average life expectancy of humans have risen to 80 or 85 years. A complete denture patient should therefore be planned between 20 to 25 years, which in other words also means that an average complete denture patient will wear 4 or 5 dentures in his state. This forms the basis of principle of preservation of residual alveolar ridges. When complete denture is worn, the tissues underlying the denture, especially the bone respond by resorption, which may vary from individual to individual. With resorbed alveolar ridges, it becomes arduous for a practitioner to find his patients satisfied. The adaptation period becomes longer and most of the patients do not understand their role in the preservation of alveolar ridges.

For a patient with a resorbed ridge, retention of the prosthesis is a concern. Much of the focus in research has been in impression making rather than the prosthesis itself. Although not universally accepted, ¹

it has been suggested that gravity and addition of weight to the mandibular denture may aid in prosthesis retention. ^{2,3} This gives rise to the hypothesis that if weight addition can improve mandibular retention, then weight reduction will aid maxillary retention. This article, therefore, aims to find out that whether a reduction of the weight of the maxillary complete denture will improve retention in a completely edentulous patient with severe maxillary residual alveolar ridge.

Clinical Case Report

An elderly male patient 73 years old, was referred to the department of Prosthodontics by department of oral diagnosis with a chief complaint of inability to wear existing dentures since last 6 months. Medical, drug and social history were non-significant. Dental history revealed that the problem with existing dentures was mainly retention, although the borders of the denture were correct. The present denture worn by the patient was his third denture and from the history, it was concluded that patients had well-formed ridges earlier. Extra oral examination revealed a decrease vertical dimension of the face, especially a very prominent nasolabial groove, mentolabial sulcus and angle of the mouth. Intra oral examination revealed severely resorbed maxillary residual alveolar ridge with obliterated vestibule due to loss of the vertical walls of the residual alveolar ridge (Fig. 1). Excess resorption of the ridge also had led to development of flabby tissue in the anterior part of the ridge that extended from right buccal frenum to left buccal frenum. The tissues were inflamed and compressible. After thorough diagnosis, a treatment plan was developed that included tissue rest, oral physiotherapy, new complete dentures (hollow maxillary denture) with semi anatomic teeth.

Regular procedures for complete denture fabrication were done till the try in procedure. After the consent for the trial dentures was taken, the denture processing for maxillary denture was modified. After dewaxing of the invested denture (Fig.2) a layer of heat cure resin (DPI-Heat cure, Dental products of India Ltd, Mumbai, India) was adapted over the body of the flask that contains artificial teeth. This was followed by application of commonly used table salt in

powdered form and in layers up to a thickness of 5 mm (Fig.3) that reached up to the level of heat cure resin placed within the mold. This was then followed by application of the same heat cure resin in the dough stage on the other side of the flask (lid) that holds the dental cast. The two were closed and the denture was processed as usual. After denture processing two small holes were made in the denture and the denture was immersed in water at room temperature which allowed dissolution of the salt and the maxillary denture was thus hollow inside (Fig. 4). The two openings were then closed by self-cure acrylic resin (DPI-Heat cure, Dental products of India Ltd, Mumbai, India). Mandibular denture on the other hand was not made hollow because the weight of the denture aids in retention. The denture was delivered to the patient and he was put on a follow up for a period of one year during which he reported satisfaction with retention of the denture (Fig. 5).

Conclusion

A simple common sense approach has been described to resolve the retention crisis in severely resorbed alveolar ridge cases. But the results are not solely because of the technique itself. It is the combination of oral physiotherapy that resolved the inflammatory state, the concept of hollowing the denture and use of semi anatomic teeth that minimized occlusal interferences and improves balance.

Discussion

Although reducing the weight of a maxillary prosthesis, has been shown to be beneficial when constructing an obturator for the restoration of a large maxillofacial defect. 4, 5 it has rarely been applied to conventional problems in complete denture fabrication. The case described in this article had resorbed maxillary residual alveolar ridge with hyperplastic flabby tissue anteriorly. Stability of the denture is an important contributor to retention of the prosthesis.

Reducing the cuspal inclination in complete denture prosthesis improves stability and thus retention. The weight reduction technique described in this article is modified from conventional techniques like the use of a dental stone, 6,7 cellophane wrapped asbestos, 8 silicone putty, 9,10 or modelling clay 11 during laboratory processing to exclude denture base material. Use of salt allows complete removal of the substance and easy closure of the opening. While

some of the salt may be lost during denture processing it is advised to keep the denture in room water after processing but before finishing.

References

1. Ohkubo C, Hosoi T. Effect of weight change of mandibular complete dentures on chewing and stability: a pilot study. *J Prosthet Dent* 1999; 82:636-42.
2. Jacobson TE, Krol AJ. A contemporary review of the factors involved in complete denture retention, stability, and support. Part I: retention. *J Prosthet Dent* 1983; 49:5-15.
3. Wormley JH, Brunton DA. Weighted mandibular dentures. *J Prosthet Dent* 1974; 32:101-2
4. Mahdy AS. Processing a hollow obturator. *J Prosthet Dent* 1969; 22:682-6.
5. Brown KE. Fabrication of a hollow-bulb obturator. *J Prosthet Dent* 1969; 21:97-103.
6. Ackerman AJ. Prosthetic management of oral and facial defects following cancer surgery. *J Prosthet Dent* 1955; 5:413-32.
7. Nidiffer TJ, Shipman TH. Hollow bulb obturator for acquired palatal openings. *J Prosthet Dent* 1957; 7:126-34.
8. McAndrew KS, Rothenberger S, Minsley GE. An innovative investment method for the fabrication of closed hollow obturator prosthesis. *J Prosthet Dent* 1998; 80:129-32.
9. Worley JL, Kniejski ME. A method for controlling the thickness of hollow obturator prostheses. *J Prosthet Dent* 1983; 50:227-9.
10. Holt RA Jr. A hollow complete lower denture. *J Prosthet Dent* 1981; 45:452-4.
11. Jhanji A, Stevens ST. Fabrication of one-piece hollow obturators. *J Prosthet Dent* 1991; 66:136-8.

Illustrations

Illustration 1

Intra Oral view showing obliterated vestibular areas with low resorbed residual alveolar ridge

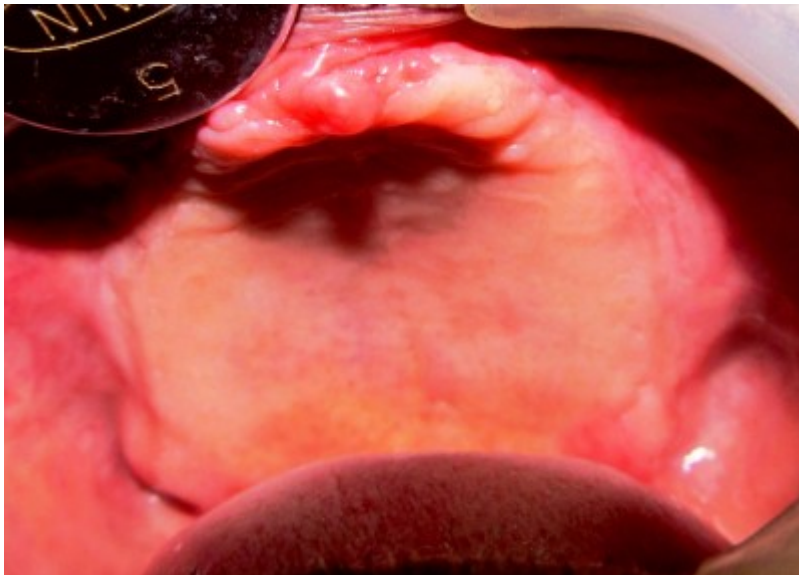


Illustration 2

Base and Body of the flask holding artificial teeth

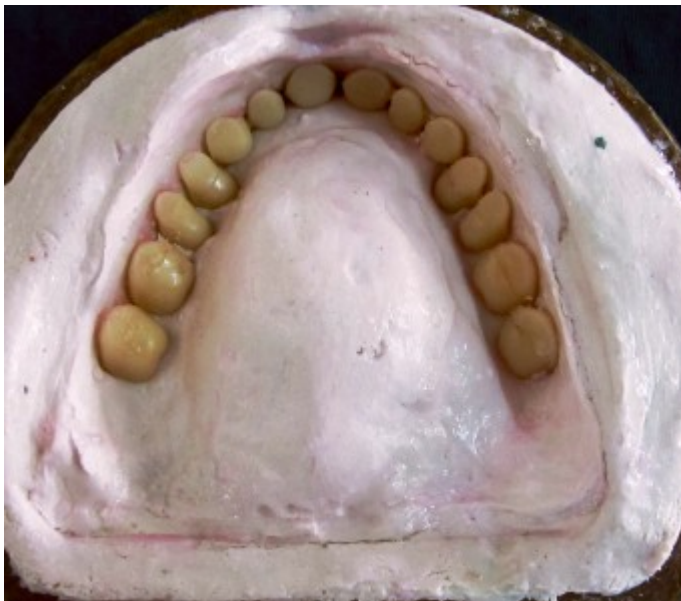

Illustration 3

Application of denture resin followed by layering of a soluble substance like common salt

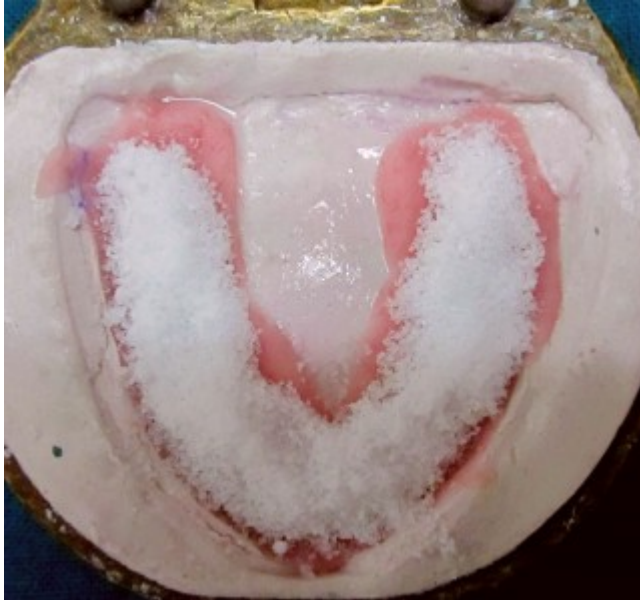

Illustration 4

Placement of denture in water at room temperature to dissolve inner soluble substance

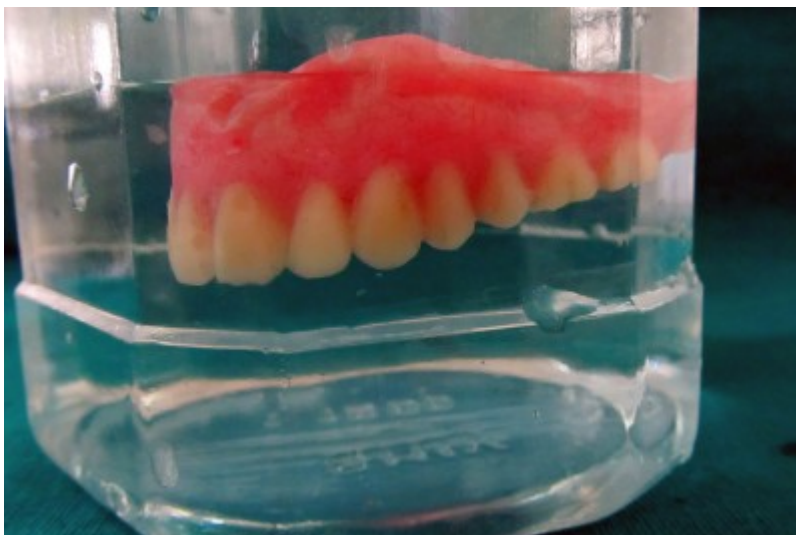

Illustration 5

Processed and finished complete denture in place

